

REVIEW ARTICLE

Dan L. Longo, M.D., *Editor*

Necrotizing Soft-Tissue Infections

Dennis L. Stevens, Ph.D., M.D., and Amy E. Bryant, Ph.D.

NECROTIZING FASCIITIS IS A SURGICAL DIAGNOSIS CHARACTERIZED BY friability of the superficial fascia, dishwasher-gray exudate, and a notable absence of pus. This and other necrotizing soft-tissue infections have multiple causes, risk factors, anatomical locations, and pathogenic mechanisms, but all such infections result in widespread tissue destruction, which may extend from the epidermis to the deep musculature.

Necrotizing infections can occur after major traumatic injuries, as well as after minor breaches of the skin or mucosa (e.g., tears, abrasions, lacerations, or insect bites), varicella infection, nonpenetrating soft-tissue injuries (e.g., muscle strain or contusion), or routine obstetrical and gynecologic procedures; they can also occur in postsurgical and immunocompromised patients (Table 1). Although necrotizing infections have common clinical features, various entities have been defined, such as progressive bacterial synergistic gangrene, synergistic necrotizing cellulitis, streptococcal gangrene, gas gangrene (clostridial myonecrosis), and nonclostridial anaerobic cellulitis. Subtle differences may distinguish one entity from another, but the clinical approaches to diagnosis and treatment are similar.

In this review, we describe the clinical and laboratory features of necrotizing fasciitis and other necrotizing soft-tissue infections. We also discuss diagnostic pitfalls and recommended treatment approaches, as well as the effect of delays in surgical intervention on mortality. (Details about pathogenic mechanisms are provided in the Supplementary Appendix, available with the full text of this article at NEJM.org.)

 EPIDEMIOLOGIC FEATURES AND CAUSES OF NECROTIZING FASCIITIS

TYPES I AND II INFECTIONS

Necrotizing fasciitis types I and II are distinguished largely by whether the cause is polymicrobial (type I) or monomicrobial (type II).¹ The annual incidence of necrotizing fasciitis ranges from 15.5 cases per 100,000 population in Thailand² to 0.3 to 5 cases per 100,000 in other regions.³⁻⁵ The relative incidence of type I and type II infections varies considerably. In some studies, type II infections have accounted for 55 to 87% of all cases of necrotizing fasciitis,^{6,7} whereas type I infections have been more prevalent, by a factor of approximately 2, in other studies,^{8,9} and in some studies, the incidence of the two types of infection has been similar.¹⁰⁻¹²

Necrotizing fasciitis type I is a polymicrobial infection involving aerobic and anaerobic organisms. It is usually seen in the elderly or in those with underlying illnesses. Predisposing factors include diabetic or decubitus ulcers, hemorrhoids, rectal fissures, episiotomies, and colonic or urologic surgery or gynecologic procedures. Type I infection is often associated with gas in the tissue and thus is

From the Veterans Affairs Medical Center, Boise, ID; and the University of Washington School of Medicine, Seattle. Address reprint requests to Dr. Bryant at the Veterans Affairs Medical Center, Infectious Diseases Section, 500 W. Fort St. (Mail Stop 151), Boise, ID 83702, or at amy.bryant@va.gov.

N Engl J Med 2017;377:2253-65.

DOI: 10.1056/NEJMra1600673

Copyright © 2017 Massachusetts Medical Society.

Table 1. Factors Conferring a Predisposition to Specific Necrotizing Soft-Tissue Infections.*

Predisposing Factor	Clinical Syndrome	Etiologic Agent
Major penetrating trauma: crush or deeply penetrating wound	Gas gangrene	<i>Clostridium perfringens</i> , <i>C. histolyticum</i> , or <i>C. novyi</i>
Minor penetrating trauma	NF type II	
Freshwater laceration		<i>Aeromonas hydrophila</i>
Saltwater laceration		<i>Vibrio vulnificus</i>
Minor nonpenetrating trauma: muscle strain, sprain, or contusion	NF type II or streptococcal myonecrosis	<i>Streptococcus pyogenes</i>
Mucosal breach: mucosal tear (rectal, vaginal, urethral); gastrointestinal, genitourinary or gynecologic surgery	NF type I	Mixed aerobic and anaerobic organisms
Skin breach		
Varicella lesions	NF type II or streptococcal myonecrosis	<i>S. pyogenes</i>
Insect bites	NF type II or streptococcal myonecrosis	<i>S. pyogenes</i>
Injection drugs	Gas gangrene	<i>C. perfringens</i> , <i>C. histolyticum</i> , <i>C. novyi</i> , or <i>C. sordellii</i>
Immunocompromised state		
Diabetes with peripheral vascular disease	NF type I	Mixed aerobic and anaerobic organisms
Cirrhosis and ingestion of raw oysters	NF type II	<i>V. vulnificus</i>
Neutropenia	Gas gangrene	<i>C. septicum</i>
In women: pregnancy, childbirth, abortion (spontaneous or medically induced), gynecologic procedures or surgery	NF type II, streptococcal myonecrosis, or clostridial myonecrosis	<i>S. pyogenes</i> , <i>C. perfringens</i> , or <i>C. sordellii</i>
Occult factors: colonic lesions, including carcinoma	Spontaneous gas gangrene	<i>C. septicum</i>

* Gas gangrene is also known as clostridial myonecrosis.

difficult to distinguish from gas gangrene. Non-clostridial anaerobic cellulitis and synergistic necrotizing cellulitis are type I variants. Both occur in patients with diabetes and typically involve the feet, with rapid extension into the leg. Though nonnecrotizing cellulitis is common in patients with diabetes, necrotizing fasciitis should be considered in patients with systemic manifestations of sepsis, such as tachycardia, leukocytosis, acidosis, or marked hyperglycemia.

Bacterial penetration into the fascial compartments of the head and neck may result in Ludwig's angina (i.e., infection of the submandibular fascial spaces) or Lemierre's syndrome (thrombophlebitis of the jugular vein), with or without severe sepsis.^{13,14} Breach of the gastrointestinal or urethral mucosa may result in Fournier's gangrene, which begins abruptly with severe pain and may spread rapidly from the perineal region to the anterior abdominal wall, the gluteal muscles, and in males, the genitalia. Finally, an indolent polymicrobial infection known

as progressive bacterial synergistic gangrene or large phagedenic ulcer¹⁵ can follow surgery involving colostomy sites or wire sutures. Though large ulcerations often develop, the process does not involve the fascia.

Necrotizing fasciitis type II is a monomicrobial infection (Table 1). Among gram-positive organisms, group A streptococcus remains the most common pathogen,^{2,4,7,11,16} followed by methicillin-resistant *Staphylococcus aureus* (MRSA).^{17,18} Unlike type I infections, type II infections may occur in any age group and in persons without any underlying illness.

Other pathogens include *Aeromonas hydrophila* and *Vibrio vulnificus*. Some experts have proposed that infections with these microbes, and possibly clostridial species, be classified as necrotizing fasciitis type III. Monomicrobial necrotizing fasciitis due to gram-negative pathogens (bacteroides and *Escherichia coli*) has also been reported,^{6,19-21} though these infections are typically seen in immunocompromised, diabetic, obese,

or postoperative patients or in those with pre-existing, chronic organ dysfunction and are not typically classified as necrotizing fasciitis type II. Resolution of these nomenclature issues requires a consensus among international infectious disease physicians, surgeons, and intensive care practitioners.

The classic clinical and histologic features of necrotizing group A streptococcal and clostridial infections are mediated by potent bacterial exotoxins and by the host response. For details, see the Supplementary Appendix.

INVASIVE GROUP A STREPTOCOCCAL SOFT-TISSUE INFECTIONS

A 2005 report estimated that more than 18 million people worldwide have invasive *Streptococcus pyogenes* diseases,²² including postpartum infections.²³ In developed countries, the annual incidence of invasive infections has remained steady at 3 to 5 cases per 100,000 population,^{3,24,25} with an average mortality of 29%.^{24,26} Mortality is higher among patients in whom streptococcal toxic shock syndrome or septic shock develops (38% and 45%, respectively).^{24,25}

Two distinct clinical presentations have been described: infection with a defined portal of bacterial entry and infection that arises spontaneously in the deep tissue, without an overt wound or lesion (Fig. 1). *S. pyogenes* gains entry to the deep tissues through superficial cutaneous lesions (chickenpox vesicles, insect bites, or lacerations), after breaches of skin or mucosal integrity (due to drug injections, surgical incisions, or childbirth), or after penetrating trauma. The initial lesion may appear to be only mildly erythematous, but over a period of 24 to 72 hours, inflammation becomes extensive, the skin turns dusky and then purplish, and bullae appear. Bacteremia is frequently present, and metastatic infections may occur. Very rapidly, the skin becomes frankly gangrenous and undergoes extensive sloughing. The patient is now perilously ill, with a high temperature and extreme prostration. At this stage, mortality is high, even with appropriate treatment.^{24,27}

In approximately 50% of patients with group A streptococcal necrotizing fasciitis or myonecrosis, infection initiates deep in the soft tissues, without a portal of entry, often at sites of non-penetrating trauma (muscle strain or bruise).^{26,28,29} Initially, only fever and crescendo pain (rapid

pain escalation sufficiently severe to require ketorolac or narcotics) may be present, and such pain prompts patients to seek urgent medical care. Malaise, myalgias, diarrhea, and anorexia may also be present in the first 24 hours. Since cutaneous manifestations are absent initially, the infection is often misdiagnosed or the correct diagnosis is delayed,³⁰ and as a result, the mortality exceeds 70%.²⁸ By the time ecchymoses and bullae develop, tissue destruction is extensive, and systemic toxicity and organ failure are evident. Emergency surgery, including extensive débridement or multiple amputations, is often required to ensure survival and necessitates prolonged hospitalization.^{26,30-32} Erroneous diagnoses include severe muscle strain and deep-vein thrombophlebitis; because of the associated gastrointestinal manifestations, food poisoning may also be diagnosed in error. Although seeding of the deep tissues probably occurs through transient bacteremia from the nasopharynx, reports rarely document coexisting or antecedent symptomatic pharyngitis (unpublished data). This might be expected, given the incidence of invasive disease (18 million cases) as compared with pharyngitis (>600 million cases).²² In children, invasive streptococcal infections have been associated with varicella zoster³³⁻³⁵ and influenza virus infections,³⁶ as well as streptococcal pharyngitis,³⁷ though relatively few cases of necrotizing fasciitis have been reported.

The toxicity of group A streptococcal necrotizing fasciitis is severe and more fulminant than that described by Meleney in 1924.³⁸ Ecchymoses and bullae develop more rapidly (in 2 to 3 days) and deep-muscle involvement is more common in contemporary cases. The mortality is also higher. Using only “bear claw fasciotomy” and irrigation with Dakin’s solution (hypochlorous acid) as treatment, Meleney reported a mortality of 20%, as compared with a mortality of 30 to 80% in the current era.²⁷ Given the involvement of epidermis, dermis, subcutaneous tissue, fascia, and muscle, “necrotizing soft-tissue infection” appears to be a more accurate term than “necrotizing fasciitis” to describe the contemporary disease.

NONSTEROIDAL ANTIINFLAMMATORY DRUGS AND GROUP A STREPTOCOCCAL INFECTION

In the 1980s, an association between the use of nonsteroidal antiinflammatory drugs (NSAIDs) and the development of group A streptococcal

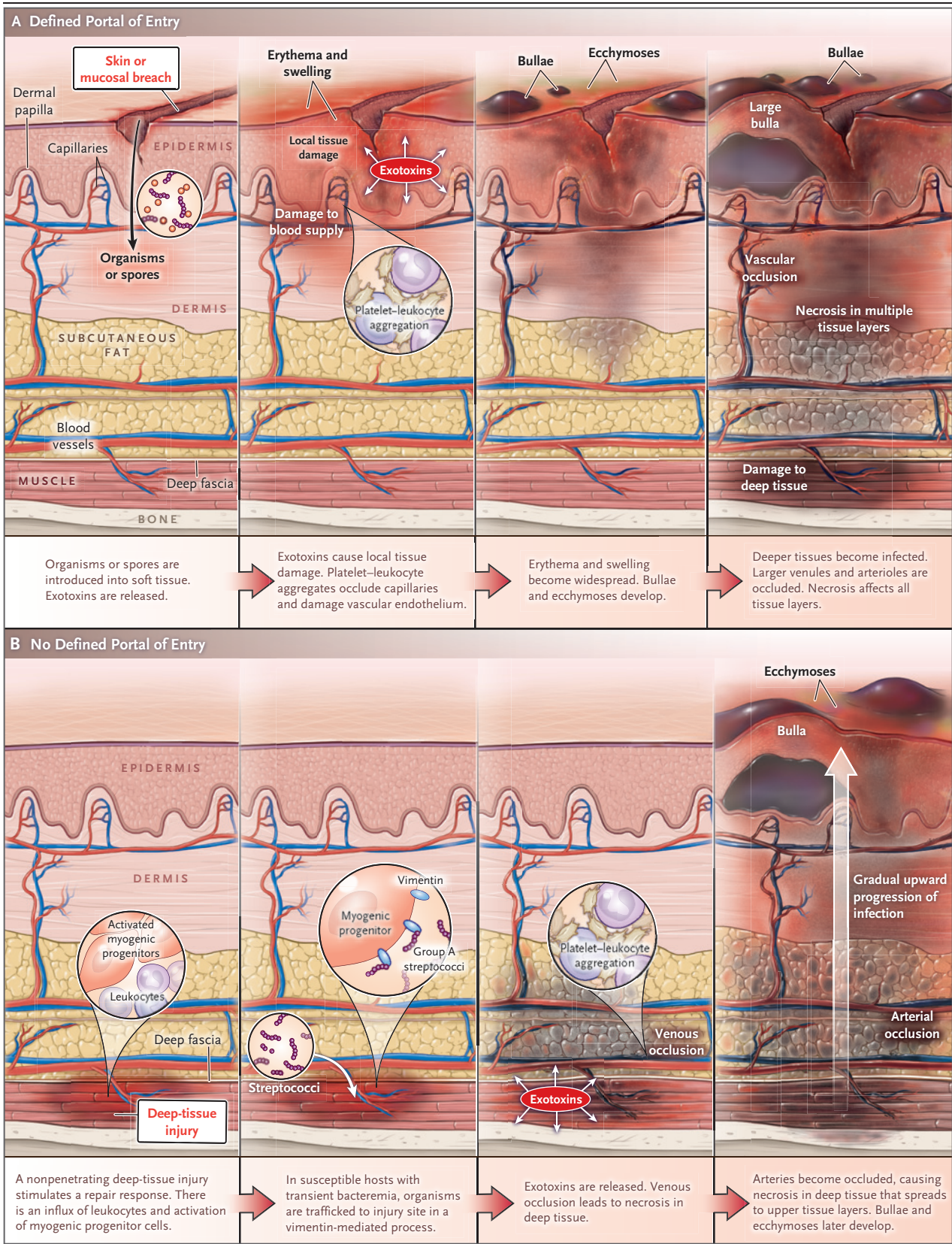


Figure 1 (facing page). Evolution of Necrotizing Fasciitis or Myonecrosis.

Panel A shows the evolution of infections with a defined portal of entry. A breach in the skin or mucosal integrity facilitates the introduction of organisms or spores into soft tissue, resulting in monomicrobial infection (with group A streptococcus, *Aeromonas hydrophila*, or *Vibrio vulnificus*) or polymicrobial infection (with both aerobes and anaerobes). Penetrating trauma sufficient to interrupt the blood supply favors the development of gas gangrene (clostridial myonecrosis). Bacteria proliferate and release exotoxins, which cause local tissue damage and impair inflammatory responses. Toxin-induced platelet–leukocyte aggregates occlude capillaries and damage the vascular endothelium, resulting in fluid leakage, tissue swelling, and erythema. Erythema and swelling become more widespread, bullae and ecchymoses develop, and deeper tissues become infected. Exotoxin production leads to occlusion of larger venules and arterioles, with subsequent ischemic necrosis of all tissue layers, from the dermis to the deep musculature. Panel B shows the evolution of group A streptococcal infection with no defined portal of entry (cryptogenic infection). A deep, nonpenetrating tissue injury such as muscle strain, sprain, or hematoma stimulates a repair response, including an influx of leukocytes and activation and proliferation of myogenic progenitor cells. In a susceptible host with a transient bacteremia (possibly arising from asymptomatic pharyngeal carriage of *Streptococcus pyogenes*), the injury leads to trafficking of the organisms to the injured site. Increased vimentin expression on activated myogenic progenitor cells and infiltrated macrophages serves as a ligand for group A streptococcus binding. Bacterial proliferation with local production of exotoxins (e.g., streptolysin O and streptococcal pyrogenic exotoxin A) ensues. Absorption of streptolysin O may stimulate intravascular accumulation of platelet–leukocyte aggregates, first in postcapillary venules and then in arterioles and larger vessels, resulting in vascular occlusion. Ischemic destruction of the deep soft tissues ensues. Cutaneous manifestations of necrotizing infection (ecchymoses and bullae) develop later in the course of infection.

necrotizing fasciitis was proposed. Proponents recognized that NSAIDs can suppress critical neutrophil functions³⁹ and augment the production of tumor necrosis factor α , a key mediator of septic shock.³⁹ Other people argued that NSAIDs merely mask the signs and symptoms of developing infection, delaying diagnosis and treatment. Numerous clinical and epidemiologic studies have investigated, but not resolved, this issue.^{40–46} Experimental evidence is limited, though two studies clearly showed that non-selective NSAIDs (e.g., ketorolac and ibuprofen) accelerated the disease course and worsened outcomes.^{47,48} In addition, ketorolac significantly

increased trafficking of circulating group A streptococci to strain-injured muscles in mice.⁴⁹

NECROTIZING CLOSTRIDIAL INFECTIONS

Gas gangrene (clostridial myonecrosis) is an acute invasion of healthy living tissue that occurs spontaneously or as a result of traumatic injury. Recurrent gas gangrene, occurring several decades after the primary infection, has also been described.⁵⁰

Deeply penetrating injuries that compromise the blood supply create an anaerobic environment that is ideal for spore germination and bacterial proliferation.⁵¹ Such trauma accounts for approximately 70% of cases of gas gangrene. Other predisposing conditions are bowel and biliary tract surgery, intramuscular epinephrine injection, retained placenta, prolonged rupture of the membranes, and intrauterine fetal death. *Clostridium perfringens* causes approximately 80% of such infections; other pathogens include *C. septicum*, *C. novyi*, and *C. histolyticum*.

Data regarding contamination versus active infection of traumatic wounds come from studies performed during World Wars I and II. In 1915, Fleming documented that 60.4% of war wounds were contaminated with clostridia.⁵² Yet MacLennan⁵³ found that active infection (gas gangrene or “anaerobic cellulitis”) occurred in fewer than 10 patients per 1000 wounded.⁵⁴ In 1941, Qvist⁵⁵ suggested that anaerobic cellulitis required only débridement of tissue that was damaged by trauma itself, whereas in gas gangrene, amputation was necessary to control rapid invasion of healthy tissue and thus ensure survival — a premise that guides clinical practice today.

Spontaneous (nontraumatic) gas gangrene is commonly caused by *C. septicum*, which is more aerotolerant than other clostridial pathogens.⁵⁶ Most infections occur in patients with gastrointestinal portals of entry such as adenocarcinoma⁵⁶ or in those with congenital or cyclic neutropenia.⁵⁷ *C. sordellii* infections can affect women after natural childbirth, as well as after abortion or other gynecologic procedures. Such infections can also develop in men, women, and children after traumatic injuries and surgical procedures or illicit-drug injection.⁵⁸ Common sites include the skin, muscle, uterus, and perineum. Systemic signs include an absence of fever, profound hypotension, diffuse capillary leak, hemoconcentration

Table 2. Pitfalls in the Diagnosis of Necrotizing Soft-Tissue Infection.*

Pitfall	Explanation
Absence of fever	Fever is often absent in patients with necrotizing soft-tissue infections because of NSAIDs that are self-administered or prescribed in the emergency department or in postsurgical settings. Fever is also absent in patients with necrotizing infection due to <i>C. sordellii</i> .
Absence of cutaneous manifestations	Patients with spontaneous or cryptogenic necrotizing infections (i.e., infections without an obvious bacterial portal of entry) that begin in the deep soft tissues often do not have cutaneous signs of infection until late in the course of the disease.
Attributing severe pain to injury or procedure	Severe pain is a key finding in patients with necrotizing infections. However, when such infections develop after surgery or parturition, pain may be erroneously attributed to the procedure itself. Similarly, perineal pain may be attributed to hemorrhoids, epididymitis, or vaginal or rectal trauma. Severe pain associated with spontaneous or cryptogenic infections is often wrongly attributed to muscle strain or venous thrombosis. If pain is out of proportion to the suspected cause or requires opioids or ketorolac for management, a developing necrotizing infection should be considered. Pain may be absent because of the use of narcotics or NSAIDs or because of neuropathy in patients with diabetes.
Nonspecific imaging tests	In patients with necrotizing infections, radiographs may show only edema, with no evidence of gas in the deep tissue. Since this finding is consistent with noninfectious causes (e.g., soft-tissue injury and postsurgical and postpartum conditions), it may confound the diagnosis.
Attributing systemic manifestations to other causes	Nausea, vomiting, and diarrhea may be early manifestations of toxemia from group A streptococcal infection, though they are often wrongly attributed to food poisoning or viral illness.

* NSAIDs denotes nonsteroidal antiinflammatory drugs.

(hematocrit, 50 to 80%), and a marked leukemoid reaction (white-cell count, 50,000 to 150,000 per cubic millimeter). Mortality is 70 to 100%, and death occurs within 2 to 4 days after hospital admission.

DIAGNOSIS OF NECROTIZING FASCIITIS AND OTHER NECROTIZING INFECTIONS

DIAGNOSTIC PITFALLS

Early diagnosis of necrotizing infections may be confounded by numerous factors (Table 2), as discussed below. Physicians must be aware of these potential pitfalls because delays in diagnosis and treatment have dire consequences. A basic diagnostic algorithm is shown in Figure 2.

CLINICAL FINDINGS

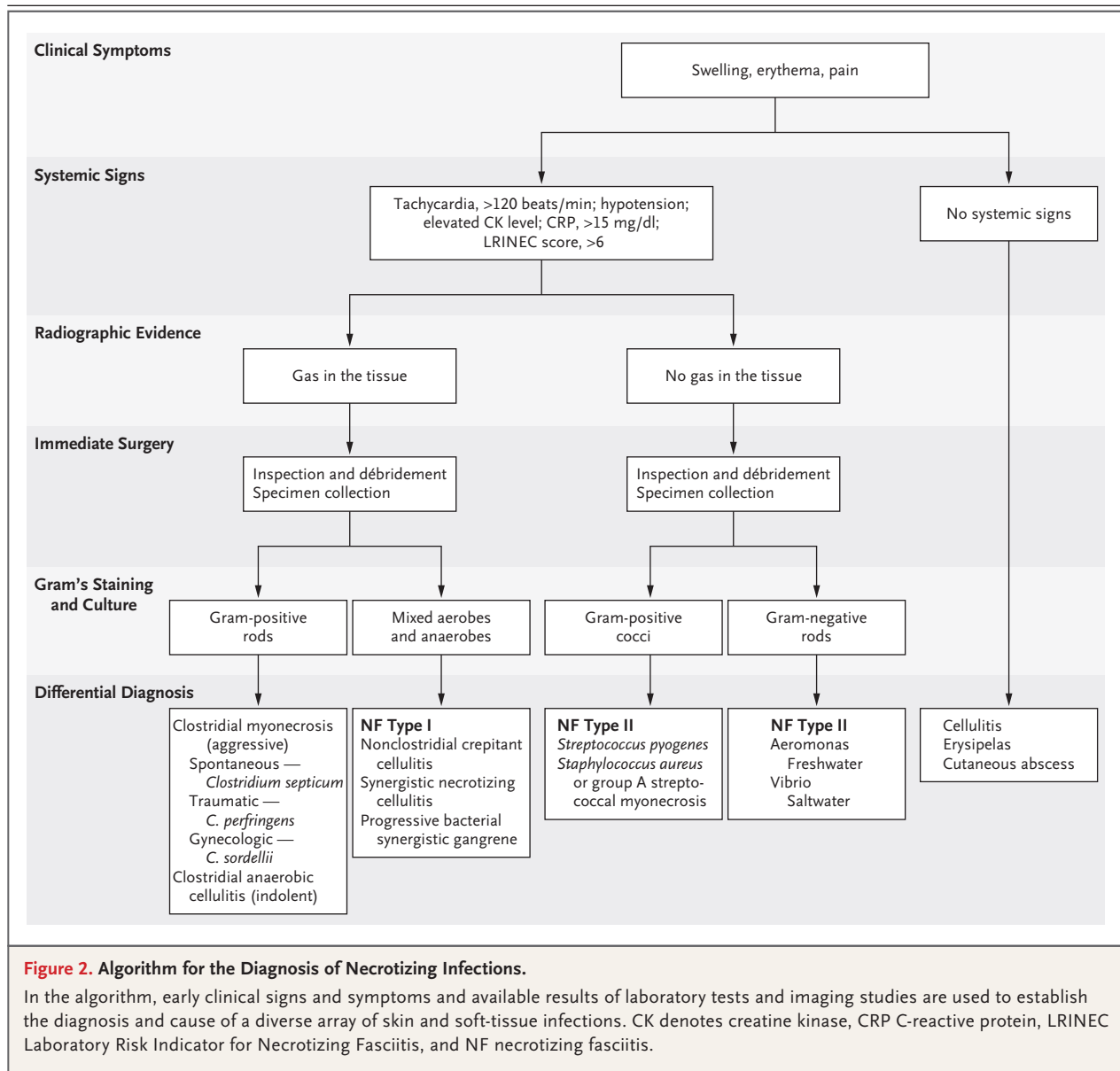
Classic manifestations of necrotizing fasciitis include soft-tissue edema (in 75% of cases), erythema (72%), severe pain (72%), tenderness (68%), fever (60%), and skin bullae or necrosis (38%).⁸ In a recent case-control study, factors that differentiated necrotizing fasciitis from cellulitis were recent surgery, pain out of proportion to clinical signs, hypotension, skin necrosis, and hemorrhagic bullae.⁹

In patients with cryptogenic group A strepto-

coccal infection (i.e., infection with no portal of entry), the process begins deep in the tissues. Crescendo pain is the most important clinical clue for such infection, and its onset typically occurs well before shock or organ dysfunction is manifested. However, crescendo pain may be absent or attenuated in patients who are receiving analgesic agents, including NSAIDs; in patients who have undergone surgery, childbirth, or trauma, the pain may be incorrectly attributed to normal postoperative soreness, typical postpartum discomfort, or the trauma itself, respectively, rather than to acute infection. Pain may also be absent in patients with altered mental status or those with diabetes-related neuropathy. In these instances, the absence of a strong clinical clue delays the correct diagnosis and appropriate treatments. Thus, all patients presenting with a sudden onset of severe pain in an extremity, with or without an obvious portal of bacterial entry or the presence of fever, should be evaluated for severe soft-tissue infection on an emergency basis.

IMAGING TESTS

Radiographs, computed tomographic (CT) scans, or magnetic resonance imaging (MRI) studies will show soft-tissue swelling in patients with group A streptococcal infection and will show



gas in the tissues of patients with gas gangrene or necrotizing fasciitis type I. Imaging evidence of gas in the tissues, or the presence of crepitus, should prompt immediate surgical consultation. A finding of swelling alone may not be useful in patients who have had a traumatic injury or have undergone surgery or childbirth, since swelling cannot be used to distinguish between infection, trauma, and inflammation. MRI may show thickening and hyperintensity of intermuscular fascia on T₂-weighted images, findings that are sensitive but not entirely specific for necrotizing fasciitis.

A study of enhanced CT in patients with documented necrotizing fasciitis as compared with those who had other musculoskeletal infections suggested that the absence of fascial enhancement was specific for necrotizing fasciitis.⁶⁰

TISSUE BIOPSY, HISTOLOGIC TESTS, AND GRAM'S STAINING

Gram's staining of surgically obtained material is crucial for determining the cause of infection and guiding empirical treatment. Percutaneous biopsy and examination of a frozen section has

been proposed to aid in the diagnosis of necrotizing infection.^{61,62} However, this technique is subject to sampling error and is not a good substitute for open surgical inspection and biopsy. Group A streptococcal necrotizing infection is characterized histologically by the destruction of muscle tissue, a paucity of infiltrating phagocytes, and large numbers of gram-positive cocci at the site (Fig. 3). The histologic findings are similar for gas gangrene, though with more evidence of edema, gas formation, or both.

SURROGATE MARKERS FOR EARLY DIAGNOSIS OF NECROTIZING FASCIITIS

A C-reactive protein level of more than 200 mg per liter,⁶³ a modestly increased white-cell count with a marked left shift,⁶⁴ and an elevated serum creatinine level in the absence of hypotension are suggestive of severe group A streptococcal infection. Marked leukemoid reactions (50 to 150,000 white cells per cubic millimeter) and profound hemoconcentration are characteristic of *C. sordellii* infection. A white-cell count of more than 15,400 per cubic millimeter plus a serum sodium level of less than 135 mmol per liter distinguishes necrotizing fasciitis in general from nonnecrotizing soft-tissue infections, with a negative predictive value of 99% but a positive predictive value of only 26%.⁶⁴ Elevated levels of serum creatine phosphokinase or serum aspartate aminotransferase suggest deep infection involving muscle or fascia (as opposed to cellulitis).

The Laboratory Risk Indicator for Necrotizing Fasciitis (LRINEC) scoring system uses the total white-cell count and hemoglobin, sodium, glucose, creatinine, and C-reactive protein levels to distinguish between mild soft-tissue infections and necrotizing fasciitis.^{65,66} For adults with LRINEC scores of 5.8 or higher (on a scale of 0 to 13, with higher scores indicating a greater likelihood of necrotizing soft-tissue infection), the positive predictive value for necrotizing fasciitis ranged from 57 to 92% in three studies,^{4,65,67} with negative predictive values of 86% and 96% in two studies.^{65,68} The disparities may be attributable, in part, to the fact that the specificity of the LRINEC score is greatest for severe disease.⁹ In a study involving children with necrotizing fasciitis, the median LRINEC score was only 3.7.⁶⁹

TREATMENT

SURGICAL INTERVENTION

For patients with aggressive soft-tissue infection or those with mild infection plus evidence of systemic toxicity, prompt surgical exploration is extremely important^{8,32,70} for three reasons: to determine the extent of infection, to assess the need for débridement or amputation, and to obtain specimens for Gram's staining and culture. When infection is near the vital structures of the neck, surgical intervention may be necessary to prevent airway obstruction. Reinspection of the surgical site within 24 hours after surgery is recommended.^{8,70} Inspection and débridement should be continued every 1 to 2 days until necrotic tissue is no longer present.^{8,32,62,70-72} Negative-pressure devices have shown promise in facilitating closure and healing of these complex wounds in small series of patients.⁷³⁻⁷⁵

There is universal agreement that early surgical débridement is crucial in managing these complex cases. But how early is early? Pinpointing the critical time for surgical intervention on the basis of published data is problematic, since the starting point for measuring the time to surgery varies among studies, particularly retrospective analyses, with some studies using the time from establishment of a definitive diagno-

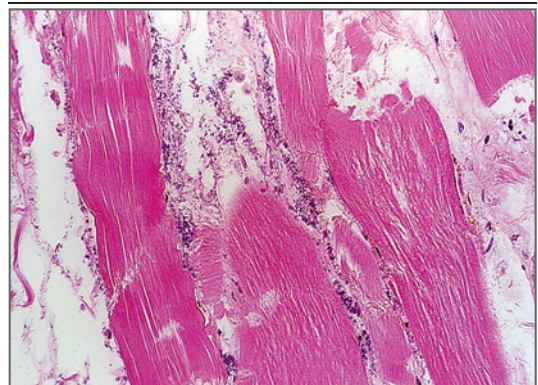


Figure 3. Histopathological Features of Group A Streptococcal Necrotizing Fasciitis and Myonecrosis.

Routine hematoxylin and eosin staining of a muscle specimen from a patient who died from cryptogenic group A streptococcal infection shows the classic features of this infection: widespread tissue destruction, lack of a tissue inflammatory response, and large numbers of bacteria in the tissues.

sis, some using the time from initial recognition of the infection, and others using the time from hospital admission. Studies at tertiary care hospitals typically report the shortest times to surgery, probably because the diagnosis was made elsewhere, before admission to the study hospital. We agree with Bandyopadhyay and colleagues⁷¹ that the definition of the time to surgery should be standardized.

Nevertheless, survival is significantly increased among patients taken to surgery within 24 hours after admission as compared with those in whom surgery is delayed for more than 24 hours.^{8,76} Survival is further increased with earlier surgical intervention (e.g., within 6 hours),^{77,78} supporting the notion that the earlier surgery is performed, the better the outcome.

PHARMACOLOGIC TREATMENT

Polymicrobial Necrotizing Infections

For mixed aerobic and anaerobic infections of the head and neck, abdomen, perineum, or gynecologic organs, definitive treatment should be based on Gram's staining, culture, and sensitivity information. Because of antibiotic resistance in gram-positive microbes and among the Enterobacteriaceae,⁷⁹ broader antibiotic coverage may be necessary, particularly if the patient has recently been hospitalized or treated with antibiotics. Treatment should also be guided by local antibiograms, since the emergence of resistance is geographically determined and specific.⁸⁰ The Infectious Diseases Society of America (IDSA) publishes guidelines for the treatment of skin and soft-tissue infections.⁷⁰ The current guidelines recommend vancomycin or linezolid plus one of the following therapies: piperacillin–tazobactam, a carbapenem, or ceftriaxone–metronidazole. Additional information on specific and alternative treatments is also provided in the IDSA guidelines. Studies are under way to evaluate ceftazidime–avibactam for highly resistant gram-negative microbes.⁸¹

Group A Streptococcal Infections

Treatment with clindamycin in combination with penicillin for 10 to 14 days is recommended for group A streptococcal infection.⁷⁰ Clindamycin monotherapy should be considered only after antibiotic susceptibility has been determined, since both constitutive and inducible resistance

in group A streptococcus have increased, to 15% in the United States⁸² and to 95.5% in China.⁸³ Treatment failures have been reported in cases of clindamycin resistance.⁸⁴ In a study of experimental myonecrosis due to group A streptococcus with resistance to erythromycin and clindamycin, tedizolid, a second-generation oxazolidinone antibiotic, was highly efficacious and superior to linezolid.⁸⁵

Other Necrotizing Fasciitis Type II Infections

Current guidelines recommend that *A. hydrophila* infections be treated with doxycycline plus either ciprofloxacin or ceftriaxone.⁷⁰ A combination of doxycycline plus either ceftriaxone or cefotaxime is recommended for *V. vulnificus* infections.⁷⁰ For MRSA infections, vancomycin, linezolid, daptomycin, or ceftaroline is likely to be effective, though such treatment has not been adequately studied.

Traumatic or Spontaneous Gas Gangrene

Treatment with penicillin plus clindamycin for 10 to 14 days is recommended for traumatic or spontaneous gas gangrene.⁷⁰ The recommendation of penicillin is based on in vitro sensitivity data. The recommendation of clindamycin is based on data showing that it is more effective than penicillin in animal models of gas gangrene caused by *C. perfringens*⁸⁶; clinical trials of clindamycin have not been performed.

CARE OF CRITICALLY ILL PATIENTS

Guidelines for the care of critically ill patients have recently been published.⁸⁷ However, problems specifically associated with necrotizing infections are of concern, as noted below.

Capillary Leak Syndrome

Circulating bacterial toxins and host mediators cause diffuse endothelial damage. Intravenous fluid requirements may be extremely high (10 to 12 liters of normal saline per day). However, profound hypoalbuminemia (0.5 to 1 g per deciliter) is also common, and replacement with colloid (albumin) may therefore be necessary to maintain oncotic pressure.

Intravascular Hemolysis

Bacterial hemolysins cause striking and rapid reductions in the hematocrit in the absence of

disseminated intravascular coagulopathy. Thus, the hematocrit may be a better indicator of the need for transfusion than the hemoglobin level.

Cardiomyopathy

Global hypokinesia, as indicated by echocardiography and cardiac output, is seen in some patients with streptococcal toxic shock syndrome.⁸⁸ Among survivors, this cardiomyopathy is reversible, fully resolving in 3 to 24 months after infection. Some patients have survived with the use of cardiac-assist devices. Management is difficult, since use of vasopressors increases afterload, resulting in decreased peripheral perfusion and reduced cardiac output. Symmetric gangrene resulting in loss of one to four extremities has been described. Careful monitoring and maintenance of mean arterial pressure so that it does not exceed 65 mm Hg in patients with this infection seem prudent, though no clinical studies have been performed to support this recommendation.

ADJUNCTIVE MEASURES

Hyperbaric Oxygen

A review of 57 studies performed between 1997 and 2003 concluded that hyperbaric oxygen is not useful for the treatment of necrotizing fasciitis,⁸⁹ a finding that is similar to the results of other studies.^{8,90,91} In contrast, a significant survival benefit of hyperbaric oxygen in necrotizing fasciitis was documented in recent studies from the United States and Australia.^{11,92} Other studies have also suggested a beneficial role of hyperbaric oxygen in the treatment of gas gangrene,^{89,91} though experimental studies showed no benefit.⁹³ Recently, a study has been initiated to evaluate the effect of hyperbaric oxygen on inflammatory and vasoactive biomarkers in necrotizing infections.⁹⁴ Meanwhile, its benefits remain controversial. Surgical débridement, which is essential for the treatment of necrotizing fasciitis, should not be delayed in order to pursue hyperbaric oxygen treatment.

Intravenous Immune Globulin

The rationale for using intravenous immune globulin (IVIG) in patients with necrotizing fas-

ciitis is based on its ability to neutralize extracellular toxins that mediate pathogenesis. Clinical studies suggesting that there are benefits to IVIG have had serious limitations, including differences in surgical intervention or clindamycin use between the group that received IVIG and the group that did not,⁹⁵ lack of power due to the small sample size,⁹⁶ low mortality in the group that did not receive IVIG,⁹⁷ and differences in the incidence of necrotizing fasciitis between the two study groups.⁹⁸ Furthermore, both the quantity and quality of neutralizing antitoxin antibodies vary from batch to batch of IVIG. In view of these limitations and the lack of data from definitive double-blind, controlled studies, the IDSA does not recommend IVIG for necrotizing group A streptococcal infections.⁷⁰ Other investigators are in agreement.⁷² In a well-controlled 2017 study involving 4127 patients with necrotizing fasciitis and streptococcal toxic shock syndrome in 130 hospitals in the United States, IVIG had no effect on mortality or length of hospital stay.⁹⁹ Thus, though IVIG has its advocates, a consensus supporting its use has not been reached.

Other Measures

A phase 2 trial of a new inhibitor of bacterial superantigens showed no significant benefit with respect to survival, number of surgical débridements, or serum cytokine levels.¹⁰⁰

SUMMARY

Necrotizing soft-tissue infections share many clinical and pathological features, and all such infections result in extensive tissue destruction. No single clinical laboratory test or group of tests can adequately replace surgical inspection for diagnosis of these infections. Early diagnosis, prompt surgical intervention, and appropriate antibiotic treatment are essential to reduce mortality and improve outcomes.

Dr. Stevens reports receiving grant support from Motif Biosciences; and Dr. Bryant, receiving grant support from Merck. No other potential conflict of interest relevant to this article was reported.

Disclosure forms provided by the authors are available with the full text of this article at NEJM.org.

REFERENCES

- Pasternack MS, Swartz MN. Cellulitis, necrotizing fasciitis, and subcutaneous tissue infections. In: Bennett JE, Dolin R, Blaser MJ, eds. Mandell, Douglas, and Bennett's Principles and practice of infectious diseases. 8th ed. Philadelphia: Elsevier, 2015:1194-215.
- Khamnuan P, Chongruksut W, Jearwattananok K, Patumanond J, Tantraworasin A. Necrotizing fasciitis: epidemiology and clinical predictors for amputation. *Int J Gen Med* 2015;8:195-202.
- Naseer U, Steinbakk M, Blystad H, Caugant DA. Epidemiology of invasive group A streptococcal infections in Norway 2010-2014: a retrospective cohort study. *Eur J Clin Microbiol Infect Dis* 2016;35:1639-48.
- Glass GE, Sheil F, Ruston JC, Butler PE. Necrotising soft tissue infection in a UK metropolitan population. *Ann R Coll Surg Engl* 2015;97:46-51.
- Bocking N, Matsumoto CL, Loewen K, et al. High incidence of invasive group A streptococcal infections in remote indigenous communities in northwestern Ontario, Canada. *Open Forum Infect Dis* 2016;4(1):ofw243.
- Jabbour G, El-Menyar A, Peralta R, et al. Pattern and predictors of mortality in necrotizing fasciitis patients in a single tertiary hospital. *World J Emerg Surg* 2016;11:40.
- Nordqvist G, Walldén A, Brorson H, Tham J. Ten years of treating necrotizing fasciitis. *Infect Dis (Lond)* 2015;47:319-25.
- McHenry CR, Piotrowski JJ, Petrincic D, Malangoni MA. Determinants of mortality for necrotizing soft-tissue infections. *Ann Surg* 1995;221:558-63.
- van Stigt SF, de Vries J, Bijker JB, et al. Review of 58 patients with necrotizing fasciitis in the Netherlands. *World J Emerg Surg* 2016;11:21.
- Wong CH, Chang HC, Pasupathy S, Khin LW, Tan JL, Low CO. Necrotizing fasciitis: clinical presentation, microbiology, and determinants of mortality. *J Bone Joint Surg Am* 2003;85-A:1454-60.
- Devaney B, Frawley G, Frawley L, Pilcher DV. Necrotising soft tissue infections: the effect of hyperbaric oxygen on mortality. *Anaesth Intensive Care* 2015; 43:685-92.
- Kulasegaran S, Cribb B, Vandal AC, McBride S, Holland D, MacCormick AD. Necrotizing fasciitis: 11-year retrospective case review in South Auckland. *ANZ J Surg* 2016;86:826-30.
- Suzuki K, Hayashi Y, Otsuka H, et al. Case report: a case of Lemierre's syndrome associated with necrotizing fasciitis and septic embolization. *Nihon Naika Gakkai Zasshi* 2016;105:99-104. (In Japanese.)
- Tawa A, Larmet R, Malledant Y, Seguin P. Severe sepsis associated with Lemierre's syndrome: a rare but life-threatening disease. *Case Rep Crit Care* 2016;2016:1264283.
- Luckett WH. VII. Large phagedenic ulcer of the abdomen. *Ann Surg* 1909;50: 605-8.
- Arif N, Yousfi S, Vinnard C. Deaths from necrotizing fasciitis in the United States, 2003-2013. *Epidemiol Infect* 2016; 144:1338-44.
- Cheng NC, Wang JT, Chang SC, Tai HC, Tang YB. Necrotizing fasciitis caused by *Staphylococcus aureus*: the emergence of methicillin-resistant strains. *Ann Plast Surg* 2011;67:632-6.
- Miller LG, Perdreaux-Remington F, Rieg G, et al. Necrotizing fasciitis caused by community-associated methicillin-resistant *Staphylococcus aureus* in Los Angeles. *N Engl J Med* 2005;352:1445-53.
- Tsai YH, Shen SH, Yang TY, Chen PH, Huang KC, Lee MS. Monomicrobial necrotizing fasciitis caused by *Aeromonas hydrophila* and *Klebsiella pneumoniae*. *Med Princ Pract* 2015;24:416-23.
- Yahav D, Duskin-Bitan H, Eliakim-Raz N, et al. Monomicrobial necrotizing fasciitis in a single center: the emergence of Gram-negative bacteria as a common pathogen. *Int J Infect Dis* 2014;28:13-6.
- Lee CY, Kuo LT, Peng KT, Hsu WH, Huang TW, Chou YC. Prognostic factors and monomicrobial necrotizing fasciitis: gram-positive versus gram-negative pathogens. *BMC Infect Dis* 2011;11:5.
- Sims SA, Colquhoun S, Wyber R, Carapetis JR. Global disease burden of group A streptococcus. In: Ferretti JJ, Stevens DL, Fischetti VA, eds. *Streptococcus pyogenes*: basic biology to clinical manifestations. Oklahoma City: University of Oklahoma Health Sciences Center, 2016:19785-8.
- Hamilton SM, Stevens DL, Bryant AE. Pregnancy-related group A streptococcal infections: temporal relationships between bacterial acquisition, infection onset, clinical findings, and outcome. *Clin Infect Dis* 2013;57:870-6.
- Nelson GE, Pondo T, Toews KA, et al. Epidemiology of invasive group A streptococcal infections in the United States, 2005-2012. *Clin Infect Dis* 2016;63:478-86.
- Lepoutre A, Doloy A, Bidet P, et al. Epidemiology of invasive *Streptococcus pyogenes* infections in France in 2007. *J Clin Microbiol* 2011;49:4094-100.
- Stevens DL, Tanner MH, Winship J, et al. Severe group A streptococcal infections associated with a toxic shock-like syndrome and scarlet fever toxin A. *N Engl J Med* 1989;321:1-7.
- Wong CJ, Stevens DL. Serious group A streptococcal infections. *Med Clin North Am* 2013;97:721-736, xi-xii.
- Adams EM, Gudmundsson S, Yocum DE, Haselby RC, Craig WA, Sundstrom WR. Streptococcal myositis. *Arch Intern Med* 1985;145:1020-3.
- Nuwayhid ZB, Aronoff DM, Mulla ZD. Blunt trauma as a risk factor for group A streptococcal necrotizing fasciitis. *Ann Epidemiol* 2007;17:878-81.
- Bisno AL, Stevens DL. Streptococcal infections of skin and soft tissues. *N Engl J Med* 1996;334:240-5.
- Schurr M, Engelhardt S, Helgersson R. Limb salvage for streptococcal gangrene of the extremity. *Am J Surg* 1998;175: 213-7.
- Anaya DA, Dellinger EP. Necrotizing soft-tissue infection: diagnosis and management. *Clin Infect Dis* 2007;44:705-10.
- Brogan TV, Nizet V, Waldhausen JHT, Rubens CE, Clarke WR. Group A streptococcal necrotizing fasciitis complicating primary varicella: a series of fourteen patients. *Pediatr Infect Dis J* 1995;14:588-94.
- Outbreak of invasive group A streptococcus associated with varicella in a child-care center — Boston, Massachusetts, 1997. *MMWR Morb Mortal Wkly Rep* 1997;46: 944-8.
- Laupland KB, Davies HD, Low DE, Schwartz B, Green K, McGeer A. Invasive group A streptococcal disease in children and association with varicella-zoster virus infection. *Pediatrics* 2000;105:E60.
- Zakikhany K, Degail MA, Lamagni T, et al. Increase in invasive *Streptococcus pyogenes* and *Streptococcus pneumoniae* infections in England, December 2010 to January 2011. *Euro Surveill* 2011;16:19785.
- Zachariadou L, Stathi A, Tassios PT, Pangalis A, Legakis NJ, Papaparaskevas J. Differences in the epidemiology between paediatric and adult invasive *Streptococcus pyogenes* infections. *Epidemiol Infect* 2014; 142:512-9.
- Meleney FL. Hemolytic streptococcus gangrene. *Arch Surg* 1924;9:317-64.
- Stevens DL. Could nonsteroidal anti-inflammatory drugs (NSAIDs) enhance the progression of bacterial infections to toxic shock syndrome? *Clin Infect Dis* 1995;21:977-80.
- Aronoff DM, Bloch KC. Assessing the relationship between the use of nonsteroidal antiinflammatory drugs and necrotizing fasciitis caused by group A streptococcus. *Medicine (Baltimore)* 2003;82: 225-35.
- Lesko SM. The safety of ibuprofen

- suspension in children. *Int J Clin Pract Suppl* 2003;135:50-3.
42. Lamagni TL, Neal S, Keshishian C, et al. Severe *Streptococcus pyogenes* infections, United Kingdom, 2003-2004. *Emerg Infect Dis* 2008;14:202-9.
 43. Dubos F, Hue V, Grandbastien B, Cateau B, Martinot A. Bacterial skin infections in children hospitalized with varicella: a possible negative impact of non-steroidal anti-inflammatory drugs? *Acta Derm Venereol* 2008;88:26-30.
 44. Mikaeloff Y, Kezouh A, Suissa S. Non-steroidal anti-inflammatory drug use and the risk of severe skin and soft tissue complications in patients with varicella or zoster disease. *Br J Clin Pharmacol* 2008;65:203-9.
 45. Leroy S, Marc E, Bavoux F, et al. Hospitalization for severe bacterial infections in children after exposure to NSAIDs: a prospective adverse drug reaction reporting study. *Clin Drug Investig* 2010;30:179-85.
 46. Das DK, Baker MG, Venugopal K. Risk factors, microbiological findings and outcomes of necrotizing fasciitis in New Zealand: a retrospective chart review. *BMC Infect Dis* 2012;12:348.
 47. Hamilton SM, Bayer CR, Stevens DL, Bryant AE. Effects of selective and non-selective nonsteroidal anti-inflammatory drugs on antibiotic efficacy of experimental group A streptococcal myonecrosis. *J Infect Dis* 2014;209:1429-35.
 48. Weng TC, Chen CC, Toh HS, Tang HJ. Ibuprofen worsens *Streptococcus pyogenes* soft tissue infections in mice. *J Microbiol Immunol Infect* 2011;44:418-23.
 49. Hamilton SM, Bayer CR, Stevens DL, Lieber RL, Bryant AE. Muscle injury, vimentin expression, and nonsteroidal anti-inflammatory drugs predispose to cryptic group A streptococcal necrotizing infection. *J Infect Dis* 2008;198:1692-8.
 50. Stevens DL, Laposky LL, McDonald P, Harris I. Spontaneous gas gangrene at a site of remote injury — localization due to circulating antitoxin. *West J Med* 1988;148:204-5.
 51. Stevens DL. Clostridial myonecrosis and other clostridial diseases. In: Bennett JC, Plum F, eds. *Cecil textbook of medicine*. 20th ed. Philadelphia: W.B. Saunders, 1996:2090-3.
 52. Fleming A. On the bacteriology of septic wounds. *Lancet* 1915;186:638-43.
 53. MacLennan JD. The histotoxic clostridial infections of man. *Bacteriol Rev* 1962;26:177-276.
 54. Stewart JC. Anaerobic cellulitis. *J Am Med Assoc* 1905;45:528-35.
 55. Qvist G. Anaerobic cellulitis and gas gangrene. *Br Med J* 1941;2:217-21.
 56. Bodey GP, Rodriguez S, Fainstein V, Elting LS. Clostridial bacteremia in cancer patients: a 12-year experience. *Cancer* 1991;67:1928-42.
 57. Stevens DL, Musher DM, Watson DA, et al. Spontaneous, nontraumatic gangrene due to *Clostridium septicum*. *Rev Infect Dis* 1990;12:286-96.
 58. Aldape MJ, Bryant AE, Stevens DL. *Clostridium sordellii* infection: epidemiology, clinical findings, and current perspectives on diagnosis and treatment. *Clin Infect Dis* 2006;43:1436-46.
 59. Alayed KA, Tan C, Daneman N. Red flags for necrotizing fasciitis: a case control study. *Int J Infect Dis* 2015;36:15-20.
 60. Carbonetti F, Cremona A, Carusi V, et al. The role of contrast enhanced computed tomography in the diagnosis of necrotizing fasciitis and comparison with the Laboratory Risk Indicator for Necrotizing Fasciitis (LRINEC). *Radiol Med* 2016;121:106-21.
 61. Stamenkovic I, Lew PD. Early recognition of potentially fatal necrotizing fasciitis — the use of frozen-section biopsy. *N Engl J Med* 1984;310:1689-93.
 62. Majeski J, Majeski E. Necrotizing fasciitis: improved survival with early recognition by tissue biopsy and aggressive surgical treatment. *South Med J* 1997;90:1065-8.
 63. Chelsom J, Halstensen A, Haga T, Høiby EA. Necrotising fasciitis due to group A streptococci in western Norway: incidence and clinical features. *Lancet* 1994;344:1111-5.
 64. Wall DB, Klein SR, Black S, de Virgilio C. A simple model to help distinguish necrotizing fasciitis from nonnecrotizing soft tissue infection. *J Am Coll Surg* 2000;191:227-31.
 65. Wong CH, Khin LW, Heng KS, Tan KC, Low CO. The LRINEC (Laboratory Risk Indicator for Necrotizing Fasciitis) score: a tool for distinguishing necrotizing fasciitis from other soft tissue infections. *Crit Care Med* 2004;32:1535-41.
 66. Bechar J, Sepelripour S, Hardwicke J, Filobos G. Laboratory Risk Indicator for Necrotising Fasciitis (LRINEC) score for the assessment of early necrotising fasciitis: a systematic review of the literature. *Ann R Coll Surg Engl* 2017;99:341-6.
 67. Burner E, Henderson SO, Burke G, Nakashioya J, Hoffman JR. Inadequate sensitivity of laboratory risk indicator to rule out necrotizing fasciitis in the emergency department. *West J Emerg Med* 2016;17:333-6.
 68. Holland MJ. Application of the Laboratory Risk Indicator in Necrotising Fasciitis (LRINEC) score to patients in a tropical tertiary referral centre. *Anaesth Intensive Care* 2009;37:588-92.
 69. Putnam LR, Richards MK, Sandvall BK, Hopper RA, Waldhausen JH, Harting MT. Laboratory evaluation for pediatric patients with suspected necrotizing soft tissue infections: a case-control study. *J Pediatr Surg* 2016;51:1022-5.
 70. Stevens DL, Bisno AL, Chambers HF, et al. Practice guidelines for the diagnosis and management of skin and soft tissue infections: 2014 update by the Infectious Diseases Society of America. *Clin Infect Dis* 2014;59(2):e10-e52.
 71. Bandyopadhyay D, Jacobs JV, Panchabhai TS. What's new in emergencies, trauma and shock? The tortuous path in the management of necrotizing fasciitis: is early surgical intervention critical? *J Emerg Trauma Shock* 2016;9:1-2.
 72. Hakkarainen TW, Kopari NM, Pham TN, Evans HL. Necrotizing soft tissue infections: review and current concepts in treatment, systems of care, and outcomes. *Curr Probl Surg* 2014;51:344-62.
 73. Crew JR, Varilla R, Allandale Rocas T III, Abdul Rani S, Debabov D. Treatment of acute necrotizing fasciitis using negative pressure wound therapy and adjunctive NeuroPhase irrigation under the foam. *Wounds* 2013;25:272-7.
 74. Baharestani MM. Negative pressure wound therapy in the adjunctive management of necrotizing fasciitis: examining clinical outcomes. *Ostomy Wound Manage* 2008;54:44-50.
 75. Lee JY, Jung H, Kwon H, Jung SN. Extended negative pressure wound therapy-assisted dermatraction for the closure of large open fasciotomy wounds in necrotizing fasciitis patients. *World J Emerg Surg* 2014;9:29.
 76. Freischlag JA, Ajalal G, Busuttill RW. Treatment of necrotizing soft tissue infections: the need for a new approach. *Am J Surg* 1985;149:751-5.
 77. Bucca K, Spencer R, Orford N, Cattigan C, Athan E, McDonald A. Early diagnosis and treatment of necrotizing fasciitis can improve survival: an observational intensive care unit cohort study. *ANZ J Surg* 2013;83:365-70.
 78. Hadeed GJ, Smith J, O'Keefe T, et al. Early surgical intervention and its impact on patients presenting with necrotizing soft tissue infections: a single academic center experience. *J Emerg Trauma Shock* 2016;9:22-7.
 79. Hawser S, Hoban DJ, Badal RE, et al. Epidemiology and antimicrobial susceptibility of Gram-negative aerobic bacteria causing intra-abdominal infections during 2010-2011. *J Chemother* 2015;27:67-73.
 80. Satlin MJ, Chen L, Patel G, et al. Multi-center clinical and molecular epidemiological analysis of bacteremia due to carbapenem-resistant Enterobacteriaceae (CRE) in the CRE epicenter of the United States. *Antimicrob Agents Chemother* 2017;61(4):e02349-16.

81. Krapp F, Grant JL, Sutton SH, Ozer EA, Barr VO. Treating complicated carbapenem-resistant Enterobacteriaceae infections with ceftazidime/avibactam: a retrospective study with molecular strain characterisation. *Int J Antimicrob Agents* 2017;49:770-3.
82. DeMuri GP, Sterkel AK, Kubica PA, Duster MN, Reed KD, Wald ER. Macrolide and clindamycin resistance in group A streptococci isolated from children with pharyngitis. *Pediatr Infect Dis J* 2017;36:342-4.
83. Peng XM, Yang P, Liu S, et al. The genetic features of drug resistance to group A streptococcus and macrolides antibiotics among pediatric patients in Beijing 2012. *Zhonghua Yu Fang Yi Xue Za Zhi* 2013;47:1040-4. (In Chinese.)
84. Lewis JS II, Lepak AJ, Thompson GR III, et al. Failure of clindamycin to eradicate infection with beta-hemolytic streptococci inducibly resistant to clindamycin in an animal model and in human infections. *Antimicrob Agents Chemother* 2014;58:1327-31.
85. Bryant AE, Aldape MJ, Bayer CR, McIndoo E, Stevens DL. Efficacy of tedizolid in experimental myonecrosis caused by erythromycin/clindamycin-sensitive and -resistant group A streptococcus. In: *Proceedings and Abstracts of 2016 IDWeek*, New Orleans, October 26–30, 2016.
86. Stevens DL, Maier KA, Laine BM, Mitten JE. Comparison of clindamycin, rifampin, tetracycline, metronidazole, and penicillin for efficacy in prevention of experimental gas gangrene due to *Clostridium perfringens*. *J Infect Dis* 1987;155:220-8.
87. Rhodes A, Evans LE, Alhazzani W, et al. Surviving Sepsis Campaign: international guidelines for management of sepsis and septic shock: 2016. *Intensive Care Med* 2017;43:304-77.
88. Stevens DL, Shelly MP, Stiller R, Villaseñor-S A, Bryant AE. Acute reversible cardiomyopathy in patients with streptococcal toxic shock syndrome. In: *Proceedings of the XVIIth Lancefield International Symposium on Streptococci and Streptococcal Diseases*, Athens, June 22–26, 2008.
89. Wang C, Schwaartzberg S, Berliner E, Zarin DA, Lau J. Hyperbaric oxygen for treating wounds: a systematic review of the literature. *Arch Surg* 2003;138:272-9.
90. Jallali N, Withey S, Butler PE. Hyperbaric oxygen as adjuvant therapy in the management of necrotizing fasciitis. *Am J Surg* 2005;189:462-6.
91. Willy C, Rieger H, Vogt D. Hyperbaric oxygen therapy for necrotizing soft tissue infections: contra. *Chirurg* 2012;83:960-72. (In German.)
92. Shaw JJ, Psoinos C, Emhoff TA, Shah SA, Santry HP. Not just full of hot air: hyperbaric oxygen therapy increases survival in cases of necrotizing soft tissue infections. *Surg Infect (Larchmt)* 2014;15:328-35.
93. Stevens DL, Bryant AE, Adams K, Mader JT. Evaluation of hyperbaric oxygen therapy for treatment of experimental *Clostridium perfringens* infection. *Clin Infect Dis* 1993;17:231-7.
94. Hansen MB, Simonsen U, Garred P, Hyldegaard O. Biomarkers of necrotizing soft tissue infections: aspects of the innate immune response and effects of hyperbaric oxygenation — the protocol of the prospective cohort BIONEC study. *BMJ Open* 2015;5(5):e006995.
95. Kaul R, McGeer A, Norrby-Teglund A, et al. Intravenous immunoglobulin therapy for streptococcal toxic shock syndrome — a comparative observational study. *Clin Infect Dis* 1999;28:800-7.
96. Darenberg J, Ihendyane N, Sjölin J, et al. Intravenous immunoglobulin G therapy in streptococcal toxic shock syndrome: a European randomized, double-blind, placebo-controlled trial. *Clin Infect Dis* 2003;37:333-40.
97. Shah SS, Hall M, Srivastava R, Subramony A, Levin JE. Intravenous immunoglobulin in children with streptococcal toxic shock syndrome. *Clin Infect Dis* 2009;49:1369-76.
98. Linnér A, Darenberg J, Sjölin J, Henriques-Normark B, Norrby-Teglund A. Clinical efficacy of polyspecific intravenous immunoglobulin therapy in patients with streptococcal toxic shock syndrome: a comparative observational study. *Clin Infect Dis* 2014;59:851-7.
99. Kadri SS, Swihart BJ, Bonne SL, et al. Impact of intravenous immunoglobulin on survival in necrotizing fasciitis with vasopressor-dependent shock: a propensity score-matched analysis from 130 US hospitals. *Clin Infect Dis* 2017;64:877-85.
100. Bulger EM, Maier RV, Sperry J, et al. A novel drug for treatment of necrotizing soft-tissue infections: a randomized clinical trial. *JAMA Surg* 2014;149:528-36.

Copyright © 2017 Massachusetts Medical Society.

IMAGES IN CLINICAL MEDICINE

The *Journal* welcomes consideration of new submissions for Images in Clinical Medicine. Instructions for authors and procedures for submissions can be found on the *Journal's* website at NEJM.org. At the discretion of the editor, images that are accepted for publication may appear in the print version of the *Journal*, the electronic version, or both.